



Linear Frontal Bone Fractures - Clinical and Surgical Profile: A Retrospective Study

Bhaskar Naidu P,^{1,*} Rajan V T,¹ Truman Srinivas,¹ and Selvakumar K¹

¹Sri Ramachandra University, Chennai, India

*Corresponding author: Bhaskar Naidu P, Sri Ramachandra University, Chennai, India. E-mail: drbhaskar_naidu@hotmail.com

Received 2016 August 22; Accepted 2016 November 26.

Abstract

Background: Linear frontal bone fractures are common injuries in road traffic accidents. Pneumocephalus and CSF (cerebrospinal fluid) leak are both factors influencing their outcome. Persistent pneumocephalus and CSF leak are main indications for surgical treatment.

Objectives: Surgical indications are rarely discussed in linear frontal bone fractures. We report results on patients with linear frontal bone fractures, clinical data, management, surgical indications and outcome.

Methods: From 2011 to 2015, 121 patients were admitted to our institution with a diagnosis of frontal bone fractures (compound depressed fractures excluded). Fractures were classified into three types, Type A: fracture involving anterior wall of the frontal sinus; Type B: fracture involving posterior wall of the frontal sinus and Type C: fracture of frontobasal region without involving the frontal sinus. All patients were followed for more than 6 months.

Results: A total of 112 patients were conservatively treated with standard pneumocephalus protocol. Nine patients underwent surgical intervention. The indications for surgery were the presence of persistent pneumocephalus in CT scan and persistent CSF leak. The presence of pneumocephalus or CSF leak in Type B patients sinus cranialisation with repair of the defect were the variables mainly influencing the outcome ($P < 0.001$).

Conclusions: Frontal bone fracture needs careful attention to prevent its complications such as a CSF leak and meningitis. Patients need clinical and radiological evaluation. Patients with persistent CSF leak or pneumocephalus should always be treated surgically and others should be managed conservatively.

Keywords: Linear Frontal Bone Fracture, CSF Leak, Surgical Management

1. Background

Linear frontal bone fractures are one of the most common injuries following road traffic accidents. Anterior skull base fractures involving the frontal bone are seen following a head injury (1). There may be isolated frontal bone fractures with or without involvement of other structures of the brain. The associated injuries noted are epidural/subdural/intraparenchymal hematomas, cerebral contusion or dural laceration. Anterior cranial base is formed by the frontal, sphenoid and ethmoid bones. It has been divided into lateral and medial regions for clinical, anatomical and radiological consideration. The posterior wall of the frontal sinus forms the anterior limit. Cribriform plate forms the medial portion, anteriorly by the ethmoid bone and posteriorly by planum sphenoidale. The lateral portion is formed by the smaller wing of the sphenoid bone and frontal bone (2). Frontal cranial base fractures have been classified in different ways in literature (3-8). Surgical indications for anterior skull base fractures are still de-

batable. The presence of pneumocephalus in brain imaging is a predicting factor for CSF leak. Persistent pneumocephalus and CSF leak are indications for surgery.

2. Objectives

The predicting factors for CSF leak, indications for surgery and outcome of patients were analyzed retrospectively in this study.

3. Methods

This retrospective study was done from June 2011 to May 2015. A total 121 patients who were admitted with a frontal bone fracture in SRMC & RI, Chennai, India were included in this study. Linear frontal bone fractures with or without pneumocephalus were the main inclusion criteria. Patients with associated EDH, SDH, SAH or contusion were excluded from the study. All patients were evaluated

with a computed tomography (CT) three dimensional (axial, sagittal, and coronal) brain scan reconstruction. An MRI for on 9 patients with CSF leak was done on the brain. Depending on clinical, radiological and surgical indications, we categorized patients into three main types,

Type A. Fracture involving the anterior wall of the frontal sinus;

Type B. Fracture involving the posterior wall of the frontal sinus;

Type C. Fracture of the frontobasal region without involving the frontal sinus.

All three-groups of patients were analyzed retrospectively. Serial CT brain scan with bone window was done on all patients. Presence of pneumocephalus, CSF leak and meningitis were all recorded. A statistical analysis was performed (Fisher's exact test) comparing the clinical and radiological findings on the three groups.

4. Results

In our study from 2011 to 2015, a total number of 121 patients with linear frontal bone fractures were included. Clinical and radiological data are reported in [Table 1](#). In our study 52.1% [63/121] patients had a Type A fracture, 39.7% [48/121] patients had a Type B fracture and 8.2% [10/121] patients sustained a Type C fracture.

On brain CT scan, 24 (19.8%) patients showed pneumocephalus, which resolved within an average of 8 days following admission in 15 (62.5%) patients and the remaining 9 (37.5%) patients had persistent pneumocephalus. Out of 121 patients, 35 (28.9%) patients had a CSF leak, of which 26 (72.2%) patients were treated conservatively and the remaining 9 (25.7%) patients needed surgical intervention in view of persistent pneumocephalus and CSF leak. Eight patients developed meningitis in our series.

4.1. Conservative Group

In this group the mean age of the patients was 41 years (range 9 to 83 years); 70 (62.5%) patients were males (76%) and 42 (37.5%) females. Type A had 63, Type B had 31 and Type C had 18 patients. Group A, with 63 patients, showed an anterior frontal sinus fracture with no radiological signs of displacement or deformity. Type B group, which included 48 patients with linear or slightly displaced fracture (< 2 mm) of the posterior wall of the frontal sinus, with features of pneumocephalus and/or CSF leak, were treated with bed rest and observation. In Type B, out of 31 patients, 22 (70.9%) patients had a CSF leak, which were treated conservatively. In Group C, 4 patients who had a CSF leaks were treated similarly. Pneumocephalus was present in 26 (83.8%) patients in Group B and 3 (16.6%) in Group C. There were 8

(16.3%) cases of meningitis in Group B and C, which were treated with appropriate antibiotics. The average stay in the hospital was 10 days ranging from 5 to 29. Morbidity included: one case of paresthesia, one case of scar retraction and eight cases of anosmia at follow-up.

4.2. Surgery Group

A total of 9 patients underwent surgical intervention for persistent CSF leak. The mean age of patients in this group was 37.6 years (range 12 to 47 years); 7 patients were males (77.7%) and 2 females (22.3%). Indication for surgery was persistent for the pneumocephalus and CSF leak. Nasal endoscopy was done in all cases; however transcranial surgery was preferred in view of large and lateral frontal defect. Bicoronal incision was placed in all cases. We preferentially used the bicoronal approach with wide exposure of the frontal bone for bifrontal craniotomy. The pericranial flap isolated at the initial part of the surgery was to be used as an inlay graft. Once the defect is defined, it is packed with muscle fascia as an inlay graft and followed by an onlay pericranial graft. The frontal sinus was exteriorized. Fibrin glue was used to perform frontal sinus cranialization and obliteration in 2 patients. The average period of stay was 8 days, ranging from 5 to 10 days. There was no postoperative mortality. Four patients had anosmia, which recovered within the mean period of 4 months. Postoperatively, only one patient showed minimal pneumocephalus in the CT scan and had no evidence of a CSF leak.

5. Discussion

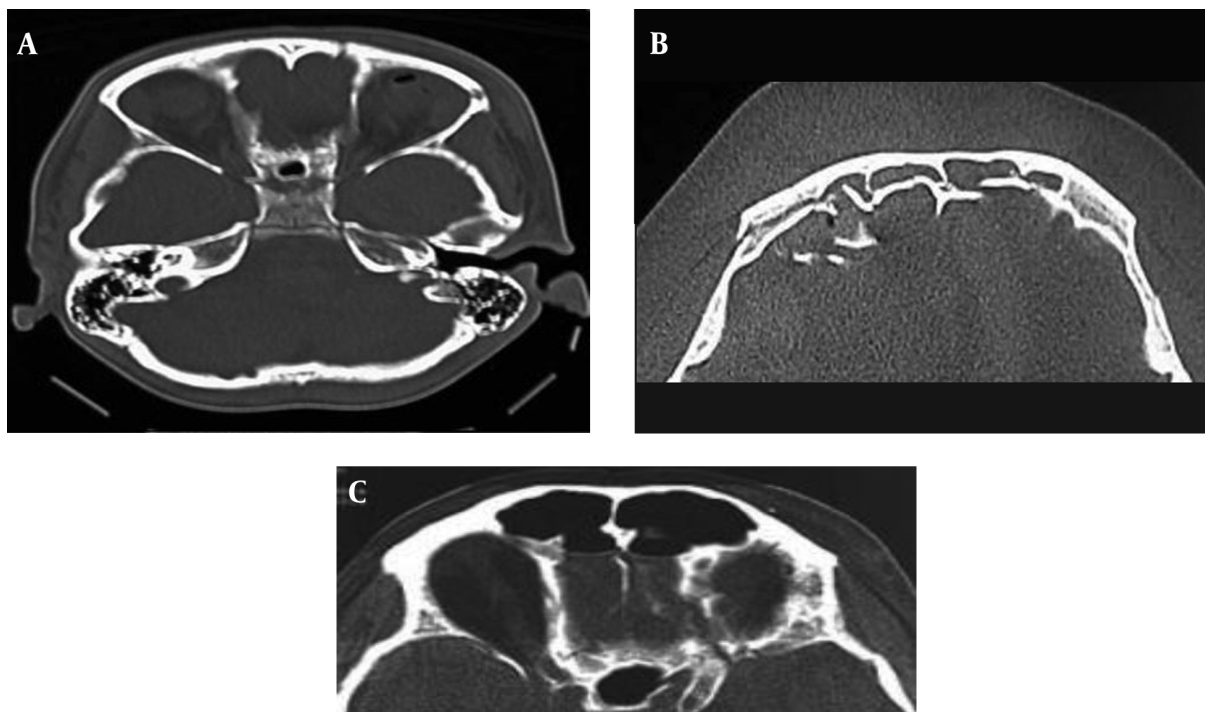
Linear frontal bone fractures are simple head injuries with morbidity if they develop CSF leak and meningitis. Initial evaluation can be done with a CT brain scan with a bone window. A simple linear frontal bone fracture requires observation. Frontal bone fractures with pneumocephalus require special attention in view of a CSF leak and meningitis ([9, 10](#)). These patients should be managed carefully with adequate bed rest and antibiotics. The clinical inspection must always test the presence of a CSF leak. The CSF leak was confirmed using $\beta 2$ transferrin test, which was helpful to obtain a differential diagnosis from mucous or serous secretions of the nose. X-rays of the skull could be a useful image tool in the diagnosis of pneumocephalus, although used in the past, today with advent of a CT scan it is outdated. In the literature, there are no clear guidelines for conservative or surgical indications in the management of frontal bone fractures. In Type A fractures, the indication for surgical treatment was the patient's facial aesthetic concern. The simple linear fracture of the frontal bone along with the sinus can be treated conservatively without a need for surgery. In patients with

Table 1. Clinical and Radiological Data

	No. of Patients	Pneumocephalus	CSF Leak	Surgical Treatment
Group A	63	0	0	0
Group B	48	22	27	7
Group C	10	2	8	2

Table 2. Conservative Group

Group	Clinical	CT Findings		Age, y	Sex	No. of Cases
	CSF Leak	Pneumocephalus	Fracture Displacement			
A	No	0	0	31	M-38, F-25	63
B	22	26	1	43	M-22, F-9	31
C	4	3	0	49	M-10, F-8	18
Total	26	29	1			112

**Figure 1.** Type A, Fracture of the Anterior Wall of Frontal Sinus; Group B, Fracture of the Posterior Wall of Frontal Sinus; Group C, Anterior Frontobasal Fractures Without Involvement of the Frontal Sinus

Type B fractures, some authors recommend that nondisplaced posterior wall fractures to be treated conservatively with close follow-up with antibiotic coverage (11, 12). However, patients with displaced fractures, CSF leak and signs of pneumocephalus show a high risk of meningitis and should be treated at the earliest with antibiotic therapy

and surgical intervention. Persistent pneumocephalus on CT scans has a high tendency towards incidence of CSF leak and should be carefully followed. In our study, the surgical treatment described should always be attempted in nondisplaced fractures with CT scans suggesting persistent pneumocephalus, since they are highly predictive

Table 3. Surgery Group

Group	Clinical	CT Findings		Age, y	Sex	No. of Cases
	CSF Leak	Pneumocephalus	Fracture Displacement			
A	0	0	0	35	Nil	0
B	7	7	2	32	M-5, F-2	7
C	2	2	1	46	M-2, F-0	2
Total	9	9	3		Nil	9

of dural laceration. In Type C patients, surgical treatment was reserved for 7 patients having fractures that are displaced and/or when patients showing signs of pneumocephalus or CSF leak. In our study, 9 patients showed one or both these findings. The frontal sinus was preserved in the majority of these patients. The subfrontal approach has proved to be safe when treating frontobasal fractures. It gives an access with a wide visibility of the anterior skull base (13-15). It allows an exposure of the posterior wall of the frontal sinus avoiding retraction of brain. Pericrainal fascia and free muscle/facial flaps were used to close the defect and fibrin glue was used as an adjunctive in only one case. There was no CSF leak noted postoperatively in any of the patients after a follow up of 6 months.

5.1. Conclusion

Linear frontal bone fractures are common fractures seen in trauma. The linear frontal bone involving the anterior wall of the frontal sinus (Group A) can be treated conservatively. Complications of frontal bone fractures are CSF leak and meningitis, which are higher if the posterior wall of the frontal sinus is involved (Group B). Frontal bone fractures with a persistent CSF leak or pneumocephalus require surgical treatment to prevent recurrent meningitis at the earliest with complications back in the mind.

References

- Rocchi G, Fadda MT, Marianetti TM, Reale G, Iannetti G. Craniofacial trauma in adolescents: incidence, etiology, and prevention. *J Trauma*. 2007;**62**(2):404-9. doi: [10.1097/01.ta.0000197627.05242.a4](https://doi.org/10.1097/01.ta.0000197627.05242.a4). [PubMed: [17297332](https://pubmed.ncbi.nlm.nih.gov/17297332/)].
- Rhoton AL. The anterior and middle cranial base. *Neurosurgery*. 2002;**51**(4 Suppl):273-302. doi: [10.1097/00006123-200210001-00007](https://doi.org/10.1097/00006123-200210001-00007). [PubMed: [12234451](https://pubmed.ncbi.nlm.nih.gov/12234451/)].
- Buitrago-Tellez CH, Schilli W, Bohnert M, Alt K, Kimmig M. A comprehensive classification of craniofacial fractures: post-mortem and clinical studies with two- and three-dimensional computed tomography. *Injury*. 2002;**33**(8):651-68. doi: [10.1016/S0020-1383\(02\)00119-5](https://doi.org/10.1016/S0020-1383(02)00119-5).
- Lee TT, Ratzker PA, Galarza M, Villanueva PA. Early combined management of frontal sinus and orbital and facial fractures. *J Trauma*. 1998;**44**(4):665-9. doi: [10.1097/00005373-199804000-00018](https://doi.org/10.1097/00005373-199804000-00018). [PubMed: [9555839](https://pubmed.ncbi.nlm.nih.gov/9555839/)].
- Ioannides C, Freihofer HP, Vrieus J, Friens J. Fractures of the frontal sinus: a rationale of treatment. *Br J Plast Surg*. 1993;**46**(3):208-14. doi: [10.1016/0007-1226\(93\)90170-G](https://doi.org/10.1016/0007-1226(93)90170-G). [PubMed: [8490699](https://pubmed.ncbi.nlm.nih.gov/8490699/)].
- Gerbino G, Rocca F, Benecch A, Caldarelli C. Analysis of 158 frontal sinus fractures: current surgical management and complications. *J Craniomaxillofac Surg*. 2000;**28**(3):133-9. doi: [10.1054/jcms.2000.0134](https://doi.org/10.1054/jcms.2000.0134). [PubMed: [10964548](https://pubmed.ncbi.nlm.nih.gov/10964548/)].
- Madhusudan G, Sharma RK, Khandelwal N, Tewari MK. Nomenclature of frontobasal trauma: a new clinico-radiographic classification. *Plast Reconstr Surg*. 2006;**117**(7):2382-8. doi: [10.1097/prs.0000218794.28670.07](https://doi.org/10.1097/prs.0000218794.28670.07). [PubMed: [16772946](https://pubmed.ncbi.nlm.nih.gov/16772946/)].
- Manson PN, Stanwix MG, Yaremchuk MJ, Nam AJ, Hui-Chou H, Rodriguez ED. Frontobasal fractures: anatomical classification and clinical significance. *Plast Reconstr Surg*. 2009;**124**(6):2096-106. doi: [10.1097/prs.0b013e3181bf8394](https://doi.org/10.1097/prs.0b013e3181bf8394).
- Yavuzer R, Sari A, Kelly CP, Tuncer S, Latifoglu O, Celebi MC, et al. Management of frontal sinus fractures. *Plast Reconstr Surg*. 2005;**115**(6):79-93. [PubMed: [15861045](https://pubmed.ncbi.nlm.nih.gov/15861045/)].
- Yilmazlar S, Arslan E, Kocaeli H, Dogan S, Aksoy K, Korfali E, et al. Cerebrospinal fluid leakage complicating skull base fractures: analysis of 81 cases. *Neurosurg Rev*. 2006;**29**(1):64-71. doi: [10.1007/s10143-005-0396-3](https://doi.org/10.1007/s10143-005-0396-3). [PubMed: [15937689](https://pubmed.ncbi.nlm.nih.gov/15937689/)].
- Castro B, Walcott BP, Redjal N, Coumans JV, Nahed BV. Cerebrospinal fluid fistula prevention and treatment following frontal sinus fractures: a review of initial management and outcomes. *Neurosurg Focus*. 2012;**32**(6):1. doi: [10.3171/2012.3.FOCUS1266](https://doi.org/10.3171/2012.3.FOCUS1266). [PubMed: [22655690](https://pubmed.ncbi.nlm.nih.gov/22655690/)].
- Raveh J, Vuillemin T, Sutter F. Subcranial management of 395 combined frontobasal-midface fractures. *Arch Otolaryngol Head Neck Surg*. 1988;**114**(10):1114-22. doi: [10.1001/archotol.1988.01860220048022](https://doi.org/10.1001/archotol.1988.01860220048022). [PubMed: [3415818](https://pubmed.ncbi.nlm.nih.gov/3415818/)].
- Kinnunen I, Aitasalo K. A review of 59 consecutive patients with lesions of the anterior cranial base operated on using the subcranial approach. *J Craniomaxillofac Surg*. 2006;**34**(7):405-11. doi: [10.1016/j.jcms.2006.04.007](https://doi.org/10.1016/j.jcms.2006.04.007). [PubMed: [16965917](https://pubmed.ncbi.nlm.nih.gov/16965917/)].
- Fliss DM, Juczer G, Cohen JT, Gatot A. The subcranial approach for the treatment of cerebrospinal fluid rhinorrhea: a report of 10 cases. *J Oral Maxillofac Surg*. 2001;**59**(10):1171-5. doi: [10.1053/joms.2001.26720](https://doi.org/10.1053/joms.2001.26720). [PubMed: [11573174](https://pubmed.ncbi.nlm.nih.gov/11573174/)].
- Donath A, Sindwani R. Frontal sinus cranialization using the pericranial flap: an added layer of protection. *Laryngoscope*. 2006;**116**(9):1585-8. doi: [10.1097/01.mlg.0000232514.31101.39](https://doi.org/10.1097/01.mlg.0000232514.31101.39). [PubMed: [16954984](https://pubmed.ncbi.nlm.nih.gov/16954984/)].